

# Which factors influence MRI in-stent lumens visibility of coronary in-stent stenosis?

## An in-vitro model investigation

Dr. G. Schönwald<sup>1,2</sup>, G. Schaefer<sup>1</sup>, Dr. G. Haltern<sup>2,3</sup>, Dr. B. Kipfmüller<sup>4</sup>

<sup>1</sup>MR:comp GmbH, MR Safety Testing Laboratory, Buschgrundstrasse 33, 45984 Gelsenkirchen, Germany, www.mrcomp.com, <sup>2</sup>University Witten/Herdecke, <sup>3</sup>HELIOS Heart Center Wuppertal, <sup>4</sup>Dept. of Physical Engineering, University of Applied Sciences, Gelsenkirchen, Germany



### I. INTRODUCTION

Today metallic stents are commonly used for treatment of occlusive artery disease (stenosis) in coronary arteries [1]. Due to the risk of in-stent restenosis caused by different factors, it is desirable to have a standardized imaging procedure, which allows non-invasive follow-up examinations.

The present gold standard for evaluating in-stent restenosis are invasive procedures such as coronary angiography [2]. A general use of MRI to evaluate in-stent restenosis in the clinical everyday life is not established [3]. Currently the direct visualization of the coronary arteries by the coronary MR-angiography (cMRA) is not feasible on account of different factors. One of the problems with the MR investigation are movement artifacts by the respiration of the patient and the independent movements of the heart. Further imaging of the coronary arteries is limited by their low diameter and the limited resolution of the MRI. Also their three-dimensional characteristics on the heart sets high requirements for the imaging procedure MRI. Finally, overlaying artifacts hamper the evaluation of the in-stent lumen [4].

As there is a high economic interest to solve the clinical and imaging problems so there is a scientific need to have an artificial material which is comparable to real stenosis. With the use of this material a standardized measuring procedure can be built up, to access the potential of the MRI to evaluate stenosis.

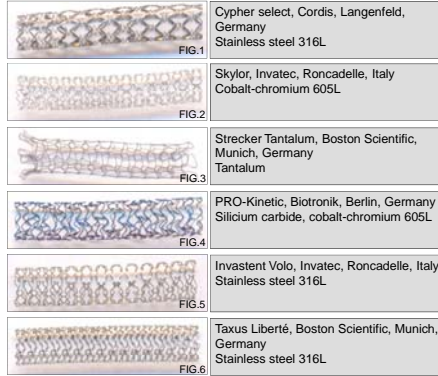
The aim of this study was to develop a static MRI in-vitro model of coronary in-stent stenosis to evaluate which stent factors need to be optimized for quantification of in-stent stenosis by analysis of lumens visibility. Six different types of balloon expanding coronary stents have been evaluated with different degrees of artificial restenosis.

- Wang Y, Truong, T, Yen C, et al. Quantitative Evaluation of Susceptibility and Shielding Effects of Nitinol, Platinum, Cobalt-Alloy, and Stainless Steel Stents. *Magnetic Resonance in Medicine* 2003, Vol 49: S. 972-976
- Léfourneau-Guilon L, Soulez G, Beaudoin G, et al. CT and MR Imaging of Nitinol Stents with Radiopaque Distal Markers. *Journal of vascular and interventional radiology* 2004, Vol 15: S. 615-624
- Buecker A, Spuentrup E, Ruebben A, et al. New Metallic MR Stents for Artifact-Free Coronary MR Angiography: Feasibility Study in a Swine Model. *Investigative Radiology* 2004, Vol 39 (5): S.250-253
- Lenhart M, Volk M, Manke C, et al. Stent Appearance at Contrast-enhanced MR Angiography: In Vitro Examination with 14 Stents. *Radiology* 2000; Vol217: S. 173-178

### II. MATERIALS AND METHODS

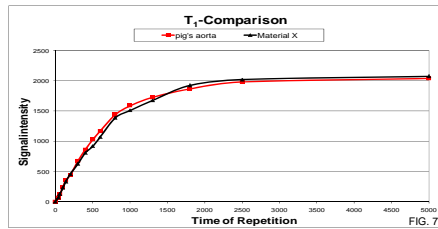
#### A. Vascular phantom and test objects

Six commercially available stents with 3.5 mm in diameter and circa 30 mm in length were tested



The static phantom was constructed on the basis of the standard F2182-02a of the American Society for Testing and Materials (ASTM). The rectangular open phantom is adapted to the human head & torso.

#### B. Artificial stenosis



A suitable material for the artificial in-stent stenosis has been selected from preliminary tests of the MRI signal parameter T1 in comparison to vascular tissue of a pig's aorta.

#### C. MR Imaging

All measurements were carried out in a 1.5 Tesla MR system (Achieva, Philips Medical Systems, Best, Netherlands). A SENSE™ Flex-M coil was used because of the position of the coronary arteries in the breast area of the human body. The test objects were positioned within the phantom parallel to the static magnetic field B<sub>0</sub>. Four different sequences were used

| Parameter              | Sequences          |                    |                          |                                   |
|------------------------|--------------------|--------------------|--------------------------|-----------------------------------|
|                        | Turbo Spin Echo T1 | Turbo Spin Echo T2 | 3D-Turbo Fast Field Echo | 3D balanced-Turbo Fast Field Echo |
| Repetition time (msec) | 500                | 2000               | 9                        | 9                                 |
| Echo time (msec)       | 20                 | 40                 | 4.5                      | 4.5                               |
| Flip angle             | 90°                | 90°                | 30°                      | 45°                               |
| field of view (mm)     | 530                | 530                | 530                      | 530                               |
| Pixel matrix           | 1024               | 1024               | 1024                     | 1024                              |
| Pixel size (mms)       | 0.52*0.52          | 0.52*0.52          | 0.52*0.52                | 0.52*0.52                         |
| slice thickness (mm)   | 5                  | 5                  | 5                        | 5                                 |
| number of slices       | 5                  | 5                  | 5                        | 5                                 |

#### D. Test setup

With stents and artificial stenosis (0%, 50% and 75%) provided tubes were arranged in the phantom.

The tubes with stenosed stents were placed in parallel and perpendicular to B<sub>0</sub> of the MR system

Around the coil SENSE™ Flex-M was fixed on the phantom. At last the completed phantom was positioned in the isocenter.



- \*First run: The tubes and the phantom were filled with 0.9% NaCl solution.
- \*Second run: The tubes were filled with 0.9% NaCl solution doped with contrast medium (Gadovist, Schering, Germany) with 0.2 mmol/kg.

#### E. Image analysis

Images were transferred to an offline workstation. For data analysis transversal images were analyzed using OSIRIS VERSION 4.19. Signal intensity profiles have been used for analysis. Distances were measured by pixel counting (0.52\*0.52 mms) in plane resolution.

### III. RESULTS

#### Parallel orientation

Within the 316L stainless steel stents, the stent lumen was completely covered by artifacts. In no image the artificial in-stent stenosis were able to evaluate.

The cobalt-chromium stents reduced the signal of the stent lumen, so that no evaluation was possible. The exception was the Skylor stent. The artificial restenosis were visible in the T2-weighted and T1-weighted TSE sequences in spite of signal reduction.

The Strecker Tantalum stent produced the lowest artifacts. Measurement of the 50% in-stent restenosis was in every used sequence possible. The 75% restenosis could be evaluated in the T2-weighted TSE and the 3D-BFFE sequence. The maximum divergence of the actual degrees of the restenosis were 7.1%.


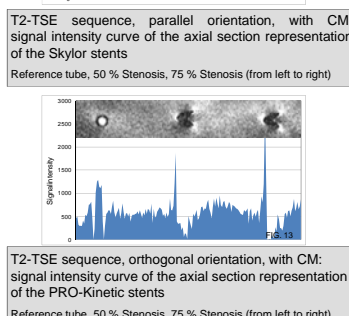
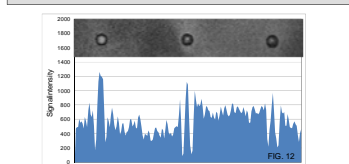
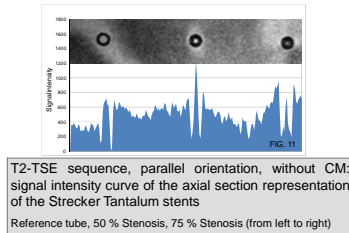
#### Orthogonal orientation

Also in the orthogonal orientation was the stent lumen completely covered by artifacts within the 316L stainless steel stents. In no image the artificial in-stent stenosis were able to evaluate, too.

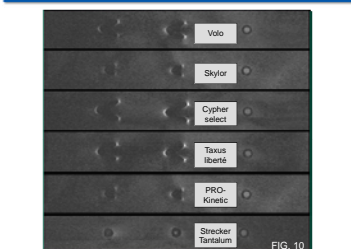
Within the cobalt-chromium stents, the in-stent lumen was voided by artifacts, so that no evaluation was possible. Also within the Skylor stent, the artificial restenosis were not visible in the T2-weighted and T1-weighted TSE sequences.

The Strecker Tantalum stent produced more artifacts in the orthogonal than in the parallel orientation. In spite of the artifacts, measurement of the 50% in-stent restenosis was possible. The 75% restenosis could only be evaluated in the T2-weighted TSE sequence.

#### Case studies



Comparison of in-stent lumens visibility (T2-TSE Imaging)  
Reference tube, 50%, 75% in-stent stenosis (from left to right)



Comparison of in-stent lumens visibility (T2-TSE Imaging)  
Reference tube, 50%, 75% in-stent stenosis (from left to right)

### IV. DISCUSSION & CONCLUSIONS

| Stent property significance to lumens visibility |                       |                  |
|--|-----------------------|------------------|
| material susceptibility                          | design                | stent thickness  |
| equal to human tissue                            | open cell structure   | thin             |
| different to human tissue                        | closed cell structure | thick            |
| p<0.0001, (n=384)                                | p<0.0001, (n=384)     | p<0.001, (n=384) |

The elective stent material has the most significant influence on the visibility of in-stent stenosis (p<0.0001, n=384). By choice of a stent material with a susceptibility towards human tissue susceptibility artifacts can be minimized.

The used stent design is an important factor of the artifact occurrence (p<0.0001, n=384). Stents with closed stent cells are worse to evaluate than those with open stent cell (Strecker Tantalum).

The stent strut thickness has also an influence on in-stent lumens visibility (p<0.001, n=384). In thin stents less eddy currents can be induced by MRI which can produce RF-Artifacts.

| MR-system property significance to lumens visibility |                                     |                 |
|--|-------------------------------------|-----------------|
| sequence   | stent orientation to B <sub>0</sub> | contrast medium |
| SE   | parallel                            | yes             |
| GRE (FFE)  | perpendicular                       | no              |
| p<0.005, (n=384)                                     | p<0.005, (n=384)                    | p<0.85, (n=384) |

Of importance is the choice of the MR sequence. Good results were achieved with the TSE sequences (p<0.005, n=384)

The stent orientation in B<sub>0</sub> has also an influence on in-stent lumens visibility. A parallel stent orientation (p<0.005, n=384) to B<sub>0</sub> reduces artifact occurrence.

Contrast medium has no significant influence on in-stent lumens visibility (p=0.85, n=384). Nearly all artificial restenosis which were visible with CM were visible without CM, too.

With choice of a low-artifact stent material (e.g. Tantalum) and a low RF-shielding design (e.g. Skylor stent) with thin stent struts an evaluation of in-stent stenosis can be possible under MRI

